REVIEW ARTICLE

CURRENT CONCEPTS

Dysfunction of the Diaphragm

F. Dennis McCool, M.D., and George E. Tzelepis, M.D.

From the Department of Pulmonary, Critical Care, and Sleep Medicine, Memorial Hospital of Rhode Island, Pawtucket (F.D.M.); the Warren Alpert Medical School of Brown University, Providence, RI (F.D.M.); and the Department of Pathophysiology, University of Athens Medical School, Athens (G.E.T.). Address reprint requests to Dr. McCool at the Department of Pulmonary, Critical Care, and Sleep Medicine, Memorial Hospital of Rhode Island, 111 Brewster St., Pawtucket, RI 02860, or at f_mccool@brown.edu.

This article (10.1056/NEJMra1007236) was updated on May 31, 2012, at NEJM.org.

N Engl J Med 2012;366:932-42.
Copyright © 2012 Massachusetts Medical Society.

The diaphragm is the dome-shaped structure that separates the thoracic and abdominal cavities. It is the principal muscle of respiration, is innervated by the phrenic nerves that arise from the nerve roots at C3 through C5, and is primarily composed of fatigue-resistant slow-twitch type I and fast-twitch type IIa myofibers.[1] Its mechanical action is best understood by considering its anatomy and its attachment to the chest wall.[2] The diaphragm abuts the lower rib cage in a region referred to as the zone of apposition (Fig. 1). As the diaphragm contracts, the abdominal contents are displaced caudally, abdominal pressure increases in the zone of apposition, and the lower rib cage expands. Disease processes that interfere with diaphragmatic innervation, contractile properties, or mechanical coupling to the chest wall can result in diaphragmatic dysfunction.[3] Such dysfunction, in turn, can lead to dyspnea, decreased exercise performance, sleep-disordered breathing, constitutional symptoms, hypersomnia, reduced quality of life, atelectasis, and respiratory failure.[4-6] This review focuses on dysfunction related to weakness and paralysis, not to anatomical abnormalities.

CLINICAL FEATURES

Diaphragmatic dysfunction is an underdiagnosed cause of dyspnea and should always be considered in the differential diagnosis of unexplained dyspnea.[7-9] Dysfunction of the diaphragm ranges from a partial loss of the ability to generate pressure (weakness) to a complete loss of diaphragmatic function (paralysis).[6,10] Diaphragmatic weakness or paralysis can involve either one or both hemidiaphragms and may be seen in the context of metabolic or inflammatory disorders, after trauma or surgery, during mechanical ventilation, and with mediastinal masses, myopathies, neuropathies, or diseases that cause lung hyperinflation.[3,4,6,11-14]

Patients with unilateral diaphragmatic paralysis are usually asymptomatic but may have dyspnea on exertion and limited ability to exercise (Table 1).[5,14-16] Occasionally, patients with unilateral diaphragmatic paralysis report dyspnea when they are supine. Coexisting conditions such as obesity, weakness of other muscle groups, or underlying heart and lung disease (e.g., chronic obstructive pulmonary disease) may worsen dyspnea in patients with unilateral diaphragmatic paralysis, especially when they are supine.[17] If patients have no symptoms, unilateral diaphragmatic paralysis may be discovered as an incidental radiographic finding of an elevated hemidiaphragm.

Patients with bilateral diaphragmatic paralysis or severe diaphragmatic weakness are more likely to have symptoms and may present with unexplained dyspnea or recurrent respiratory failure. They can have considerable dyspnea at rest, when supine, with exertion, or when immersed in water above their waist.[4,8] They often need to use a recliner for sleep and to avoid swimming or activities that require bending.[3] A history of chest surgery, manipulation of the cervical spine, neck injury, a slowly pro-

The New England Journal of Medicine
Downloaded from nejm.org at UNIVERSITY OF EDINBURGH LIB on January 28, 2019. For personal use only. No other uses without permission.
Copyright © 2012 Massachusetts Medical Society. All rights reserved.

gressive neuromuscular disease, or acute neck or shoulder pain should be sought in patients with either unilateral or bilateral diaphragmatic paralysis.[4] Patients with bilateral diaphragmatic paralysis are at an increased risk for sleep fragmentation and hypoventilation during sleep.[18,19] Consequently, initial symptoms may include fatigue, hypersomnia, depression, morning headaches, and frequent nocturnal awakenings. Other complications of bilateral diaphragmatic paralysis include subsegmental atelectasis and infections of the lower respiratory tract.

On examination, tachypnea and use of accessory muscles may be noted during quiet breathing.[4] The use of accessory muscles can be recognized by palpating the neck; the examiner can sense contraction of the sternocleidomastoid muscles during inspiratory efforts. Decreased diaphragmatic excursion may be detected by percussion of the lower rib cage at end expiration and end inspiration. The most characteristic physical sign of diaphragmatic dysfunction is abdominal paradox, which is the paradoxical inward motion of the abdomen as the rib cage expands during inspiration (Fig. 2).[4,20] This disordered breathing pattern results from compensatory use of the accessory inspiratory muscles of the rib cage and neck.[15,21] When these muscles contract and lower pleural pressure, the weakened or flaccid diaphragm moves in a cephalad direction and the abdominal wall moves inward. This paradoxical breathing pattern is most easily seen with the patient in the supine position. Abdominal paradox is typically observed when the maximum transdiaphragmatic pressure that the patient can generate against a closed airway is less than 30 cm of water[10]; it rarely occurs in unilateral diaphragmatic paralysis.[16,17] When abdominal paradox is present in unilateral diaphragmatic paralysis, it suggests generalized weakness of the respiratory muscles.[16]

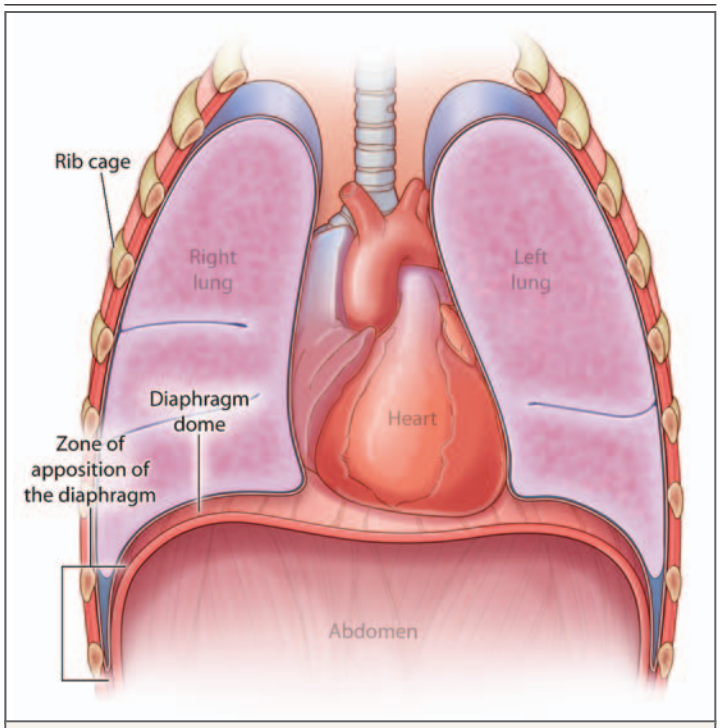

Figure 1. Anatomical Arrangement of the Diaphragm with the Rib Cage and Abdomen.
The cylindrical region of the diaphragm that apposes the lower rib cage is referred to as the zone of apposition of the diaphragm.

NATURAL HISTORY

The natural history of diaphragmatic dysfunction depends largely on its cause and the rate of progression of the underlying disease. Age-related changes in respiratory drive, respiratory-muscle strength, and chest-wall compliance may predispose patients with diaphragmatic dysfunction to hypoventilation.[18-20] In certain neuromuscular diseases (e.g., muscular dystrophies), the course of diaphragmatic dysfunction is progressive, whereas in the case of post-traumatic or infectious diaphragmatic paralysis, spontaneous recovery occurs in approximately two thirds of patients but may take a considerable amount of time.[12,13,22-25] Regeneration of the phrenic nerve, which may take up to 3 years, is necessary for recovery.[13] Patients with unilateral or bilateral diaphragmatic paralysis that is due to neuralgic amyotrophy (often marked by a history of acute shoulder or neck pain followed by dyspnea) typically have complete recovery or improvement in symptoms in 1 to 1.5 years.[13,24] Recovery times may be somewhat shorter in patients who have diaphragmatic dysfunction after cardiac surgery.[12] In contrast, the prognosis is poor for patients who have diaphragmatic dysfunction after traumatic injury to the spinal cord.[23]

CAUSES

The incidence of clinically significant diaphragmatic dysfunction is difficult to estimate, given its multiple causes.[3,4] The causes of diaphragmatic dysfunction can be classified by the level of the

The New England Journal of Medicine
Downloaded from nejm.org at UNIVERSITY OF EDINBURGH LIB on January 28, 2019. For personal use only. No other uses without permission.
Copyright © 2012 Massachusetts Medical Society. All rights reserved.

Table 1. Comparison of Bilateral and Unilateral Diaphragmatic Paralysis.*

Diagnostic Tools and Treatment	Bilateral Diaphragmatic Paralysis	Unilateral Diaphragmatic Paralysis
Presentation	Dyspnea at rest, unexplained dyspnea, exercise limitation, orthopnea, dyspnea when bending, constitutional symptoms, dyspnea when entering water, respiratory failure, prolonged mechanical ventilation	Asymptomatic, unexplained dyspnea; exercise limitation, incidental radiographic finding
History	Neck or shoulder pain, chest or neck surgery, neck injury, manipulation of the cervical spine, neuromuscular disease	Neck or shoulder pain, chest or neck surgery, neck injury, manipulation of the cervical spine, neuromuscular disease
Examination	Abdominal paradox	No abdominal paradox
Laboratory tests		
Vital capacity (% of predicted value)	<50	>70
Decline in supine vital capacity (%)	30–50	10–30
MIP (% of predicted value)	<30	>60
Fluoroscopy	Not helpful	Sniff test positive
Thickening of diaphragm on inspiration†	No change	No change
Pdi max (cm of water)	<40	>70
Twitch Pdi (cm of water)	<20	<10
Complications	Frequent hypoventilation during sleep, atelectasis, pneumonia, respiratory failure	Occasional hypoventilation during sleep, atelectasis
Treatment		
Observation period for recovery (yr)	1.5–3	1.5–3
Treatment for coexisting conditions	Yes	Yes
Reversal of metabolic disturbance	Yes	Yes
NIPPV	Often indicated	Usually not indicated
Plication of diaphragm	Not indicated	May be helpful
Phrenic pacing	Yes, in patients with high SCI	No

* MIP denotes maximal static inspiratory pressure, NIPPV noninvasive positive pressure ventilation, Pdi transdiaphragmatic pressure, Pdi max maximal inspiratory efforts against a closed glottis, SCI spinal cord injury, and twitch Pdi transcutaneous electrical or magnetic stimulation of the phrenic nerve.
† Changes in thickness of the diaphragm are measured with the use of ultrasonography of the diaphragmatic zone of apposition.

impairment and are discussed here in a rostral-to-caudal sequence (Fig. 3). With some disorders, impairment may occur at more than one anatomical level; for example, critical illness polyneuropathy may be due to both a peripheral neuropathy and myopathy.[26]

The medulla or spinal cord may be affected by demyelinating plaques. However, diaphragmatic weakness is infrequently found in multiple sclerosis.[27] High spinal cord injuries (at C1 or C2) result in diaphragmatic paralysis, whereas diaphragmatic function is partially preserved with midcervical lesions (at C3 through C5). About 40% of patients with lesions at C3 require mechanical ventilation, whereas less than 15% of patients with lesions at C4 or C5 need ventilatory support.[28] Diseases involving the lower motor neurons in the spine, such as amyotrophic lateral sclerosis or poliomyelitis, often lead to diaphragmatic dysfunction and respiratory failure. Diaphragmatic weakness may occur shortly after or many years after the initial poliomyelitis infection (mean, 35 years).[29] Other diseases that cause diaphragmatic weakness and involve spinal motor neurons include syringomyelia, paraneoplastic motor neuropathies (e.g., the anti-Hu syndrome), and spinal muscular atrophies. Respiratory failure accounts for most of the complications and deaths caused by these disorders.

Damage to the phrenic nerve is most commonly due to iatrogenic injury during surgery or to compression caused by bronchogenic or mediastinal tumors.[30,31] During cardiothoracic or neck surgery, damage of the phrenic nerve may be due to transection, stretching, crushing, or hypother-

The New England Journal of Medicine
Downloaded from nejm.org at UNIVERSITY OF EDINBURGH LIB on January 28, 2019. For personal use only. No other uses without permission.
Copyright © 2012 Massachusetts Medical Society. All rights reserved.

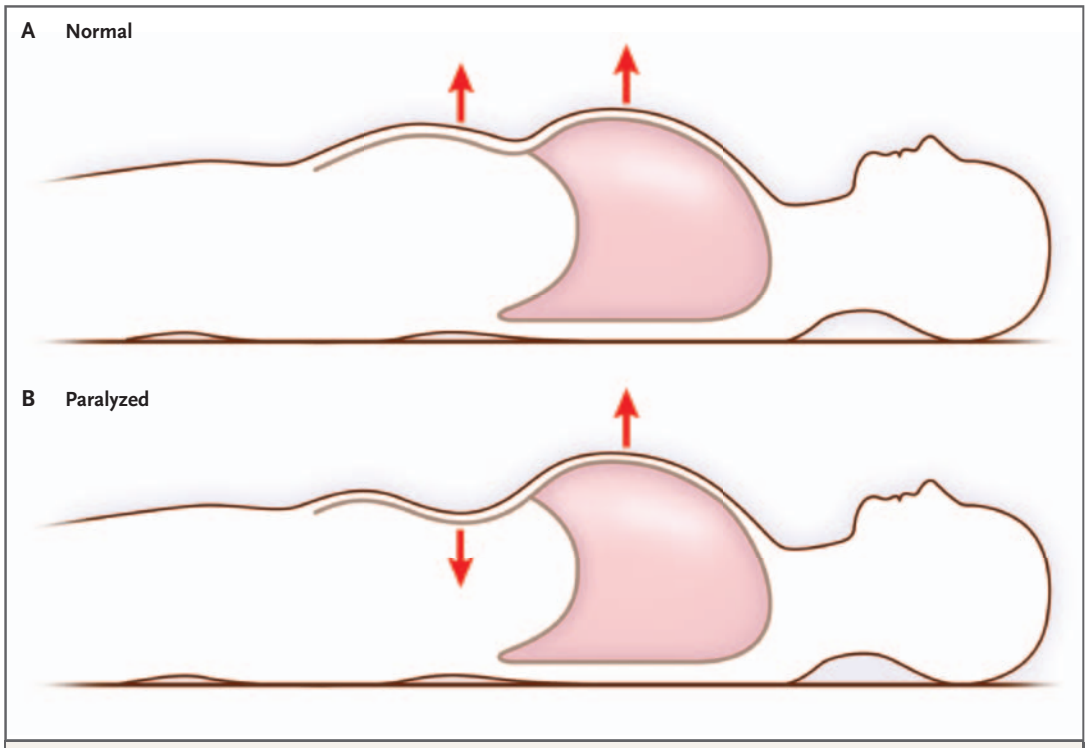

Figure 2. Comparison of Rib-Cage and Abdominal Motion in Normal and Paralyzed Diaphragms.
Panel A shows how normal diaphragmatic contraction results in an outward motion of the abdomen and rib cage (arrows). Panel B shows how diaphragmatic paralysis results in a paradoxical inward motion of the abdomen (downward-pointing arrow) during inspiration. The accessory inspiratory muscles contract, lifting the rib cage (upward-pointing arrow) and lowering the intrathoracic pressure. This change causes the flaccid diaphragm to move in a cephalad direction and the anterior abdominal wall to move inward.

mia. In cardiac surgery, the use of cold saline solutions containing ice chips or slush to lower myocardial temperature is the most important risk factor for phrenic-nerve injury.[32] The avoidance of hypothermic injury to the phrenic nerve with the use of cardiac insulation pads has significantly decreased the incidence of diaphragmatic dysfunction in these patients.[33] Other processes that can directly involve the phrenic nerve include trauma, infections (e.g., herpes zoster and Lyme disease), and inflammatory disorders. The Guillain–Barré syndrome is often complicated by phrenic-nerve involvement, with up to 25% of patients requiring mechanical ventilation.[34,35] The phrenic nerve may be involved in approximately 5% of patients with neuralgic amyotrophy (Parsonage–Turner syndrome) and in up to 2% of patients who have undergone cardiac surgery.[25,36,37]

Disordered synaptic transmission at the neuromuscular junction may be manifested as diaphragmatic dysfunction.[3,10,38] In myasthenia gravis, acute respiratory failure most often occurs during myasthenic crisis, requires ventilatory support, and usually responds to immunomodulating therapy.[3] Diaphragmatic dysfunction is not commonly seen in the Lambert–Eaton syndrome.[38] Botulinum toxins (most often type A) impair diaphragmatic function by interfering with the release of acetylcholine into the neuromuscular junction.[39] In rare cases, medications, such as aminoglycosides, interfere with neuromuscular transmission, causing diaphragmatic weakness and respiratory failure. Various inherited or acquired myopathies may impair diaphragmatic function and lead to respiratory failure early in life or in adulthood.[3,4]

Critical-illness polyneuropathy and myopathy are common causes of diaphragmatic weakness and ventilator dependency in patients in the intensive care unit.[26] They are more common among patients with sepsis, multiorgan failure, and hyperglycemia and should be considered in patients for whom weaning from ventilator support is difficult.[26] Disuse atrophy of the diaphragm can occur even after brief periods of mechanical ventilation

The New England Journal of Medicine
Downloaded from nejm.org at UNIVERSITY OF EDINBURGH LIB on January 28, 2019. For personal use only. No other uses without permission.
Copyright © 2012 Massachusetts Medical Society. All rights reserved.

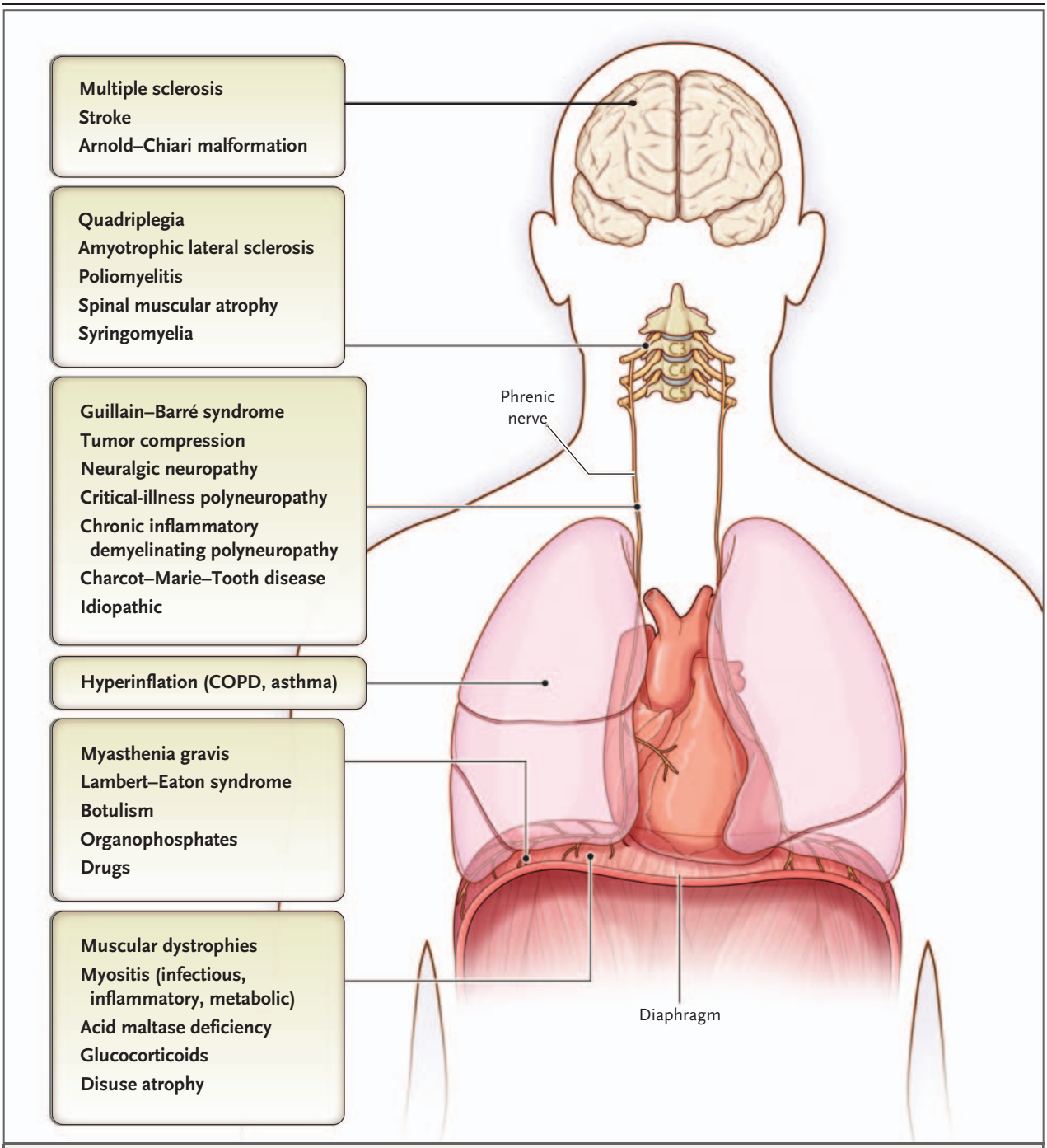

Figure 3. Causes of Diaphragmatic Dysfunction, According to Level of Impairment.
Disorders that occur at various regions in the body can lead to diaphragmatic dysfunction. COPD denotes chronic obstructive pulmonary disease.

or after the administration of paralyzing agents; it is associated with atrophy of both fast-twitch and slow-twitch myofibers.[40-42] Undernutrition and metabolic abnormalities such as hypophosphatemia, hypomagnesemia, hypokalemia, hypocalcemia, and thyroid disturbances can contribute to diaphragmatic dysfunction and prolong ventilator dependency.[43,44] The combination of diaphragmatic weakness and any process that increases the work of breathing (e.g., pneumonia, pulmonary

The New England Journal of Medicine
Downloaded from nejm.org at UNIVERSITY OF EDINBURGH LIB on January 28, 2019. For personal use only. No other uses without permission.
Copyright © 2012 Massachusetts Medical Society. All rights reserved.

edema, atelectasis, or bronchospasm) may overwhelm the capacity of even a mildly weakened diaphragm and contribute to prolonged mechanical ventilation.

Lung hyperinflation in chronic obstructive pulmonary disease impairs diaphragmatic function by shortening the diaphragm to a suboptimal length and, to a lesser extent, by impairing mechanical advantage in the diaphragm (i.e., ineffective translation of diaphragmatic tension to transdiaphragmatic pressure).[3,45,46] Therapeutic interventions, such as long-acting bronchodilators, surgery to reduce lung volume, and lung transplantation, can mitigate the negative effects of hyperinflation on diaphragmatic function by promoting lung emptying and decreasing lung volume, thereby improving the length and contractility of the diaphragm.[47-49]

DIAGNOSIS

Once suspected, diaphragmatic dysfunction can be confirmed by a number of tests. Chest radiographs may reveal elevated hemidiaphragms and basal subsegmental atelectasis.[4] However, elevation of both hemidiaphragms, as is commonly seen in patients who are ventilator-dependent, may be interpreted as a "poor inspiratory effort" or "low lung volumes" and has low specificity for diagnosing diaphragmatic dysfunction.[50] Although chest radiography is a reasonably sensitive tool for detecting unilateral diaphragmatic paralysis (90%), its specificity is unacceptably low (44%).[50]

Fluoroscopy of the diaphragm has been extensively used to evaluate diaphragmatic function. A "sniff test" consists of assessing the motion of the diaphragm during a short, sharp inspiratory effort through the nostrils. Descent of the diaphragm will be seen in persons without the disorder. With unilateral diaphragmatic paralysis, there is a paradoxical (cephalad) movement of the paralyzed hemidiaphragm. Although the sniff test may be used to diagnose unilateral diaphragmatic paralysis, it is no longer considered a helpful test in diagnosing bilateral diaphragmatic paralysis.[3] False positive results of the sniff test may occur in as many as 6% of patients without diaphragmatic paralysis.[51] False negative results can occur with active contraction of the abdominal muscles during expiration to volumes below functional residual capacity, followed by abrupt relaxation of the abdominal muscles at the onset of inspiration, resulting in caudal motion of the paralyzed diaphragm. This abrupt caudal motion at the onset of inspiration may be falsely interpreted as contraction of the diaphragm.[20]

Decisions about workup are generally made on the basis of the invasiveness and availability of testing (Fig. 4). Pulmonary-function tests, especially measurements of upright and supine vital capacity, are readily available, are noninvasive, and may support or refute the diagnosis of diaphragmatic dysfunction. With unilateral diaphragmatic paralysis, total lung capacity may be mildly restricted (70 to 79% of the predicted value).[10] In severe diaphragmatic weakness or bilateral diaphragmatic paralysis, there is typically moderate-to-severe restriction (30 to 50% of the predicted value for total lung capacity). In both unilateral and bilateral diaphragmatic paralysis, the restrictive dysfunction becomes more severe when the patient is in the supine position. A decrease in vital capacity of 30 to 50% when the patient is supine supports the diagnosis of bilateral diaphragmatic paralysis, whereas a decrease in vital capacity of 10 to 30% of the vital capacity when the patient is seated may be seen with mild diaphragmatic weakness or unilateral diaphragmatic paralysis.[14,21] When there is little or no reduction in supine vital capacity, the presence of clinically significant diaphragmatic weakness is unlikely.[10] The mechanism related to the reduction in supine vital capacity is the cephalad displacement of abdominal contents in concert with ineffective activity of the accessory inspiratory muscles.[14,21] The functional residual capacity and residual volume are usually normal in patients with unilateral diaphragmatic paralysis and are decreased in those with bilateral diaphragmatic paralysis.[14,21]

Two additional measures of diaphragmatic strength are maximal static inspiratory pressure and sniff nasal inspiratory pressure. These measurements are also noninvasive but are effort-dependent and more variable than measurements of lung volume.[52,53] Maximal static inspiratory pressure and sniff nasal inspiratory pressure are mildly reduced, to about 60% of the predicted value, in patients with unilateral diaphragmatic paralysis and are markedly reduced, to less than 30% of the predicted value, in those with bilateral diaphragmatic paralysis.[14,21] Maximal expiratory pressure is typically preserved in patients with disease processes that affect the diaphragm but spare the expiratory muscles. Concomitant reductions in maximal static inspiratory pressure and in

The New England Journal of Medicine
Downloaded from nejm.org at UNIVERSITY OF EDINBURGH LIB on January 28, 2019. For personal use only. No other uses without permission.
Copyright © 2012 Massachusetts Medical Society. All rights reserved.

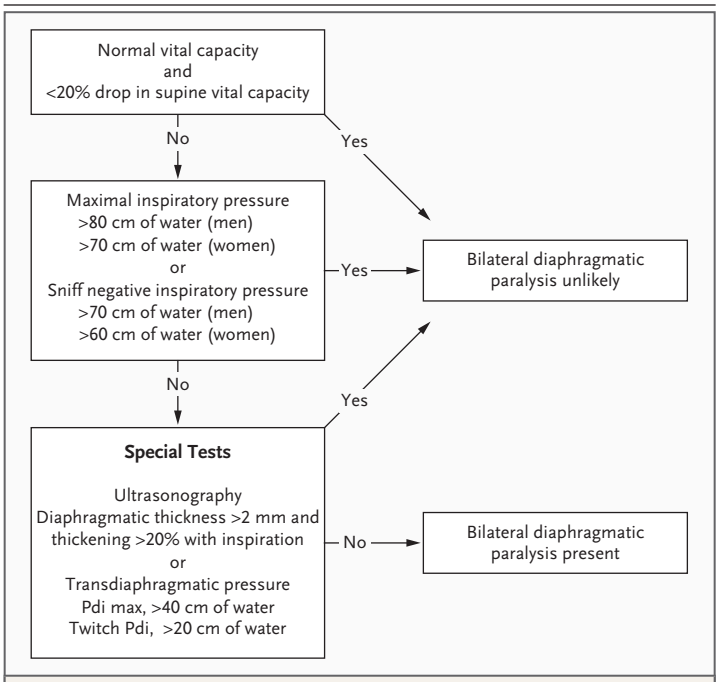

Figure 4. Diagnostic Algorithm for Bilateral Diaphragmatic Paralysis. This flowchart shows the diagnostic tests that are useful in evaluating whether a patient has bilateral diaphragmatic paralysis. Pdi denotes transdiaphragmatic pressure, Pdi max a Pdi measured during maximal inspiratory efforts against a closed glottis, and twitch Pdi a Pdi measured with transcutaneous electrical or magnetic stimulation of the phrenic nerve.

Videos showing ultrasonography of normal and paralyzed diaphragms are available at NEJM.org

maximal expiratory pressure suggest that the cause of the diaphragmatic dysfunction is a generalized process involving both the inspiratory and expiratory muscles (e.g., muscular dystrophy).[21,37] However, a mild reduction in maximal expiratory pressure (70 to 80% of the predicted value) may simply reflect suboptimal length–tension properties of the expiratory muscles at a restricted total lung capacity, rather than a generalized myopathic process.

Direct measures of diaphragmatic function can be classified as invasive (e.g., transdiaphragmatic pressure [Pdi]) or noninvasive (e.g., ultrasonography). These tests may not be offered at some institutions but may be required when the diagnosis remains uncertain. Measurement of Pdi requires transnasal placement of balloon catheters in the lower esophagus and stomach (Fig. 1 in the Supplementary Appendix, available with the full text of this article at NEJM.org). Pdi is calculated as the difference between the gastric and esophageal pressures. It can be measured during tidal breathing, maximal sniff maneuvers (sniff Pdi), maximal inspiratory efforts against a closed glottis (Pdi max), or transcutaneous electrical or magnetic stimulation of the phrenic nerve (twitch Pdi). A sniff Pdi or Pdi max greater than 80 cm of water in men and greater than 70 cm of water in women rules out clinically significant diaphragmatic weakness.[52,53] A twitch Pdi greater than 10 cm of water with unilateral phrenic-nerve stimulation or greater than 20 cm of water with bilateral phrenic-nerve stimulation also rules out clinically significant weakness.[53] Twitch Pdi is a useful means of assessing diaphragmatic function in cases in which there is an inability to perform the maneuvers required for the other Pdi tests or separate evaluation of each hemidiaphragm is necessary.[53] Although measurement of Pdi is generally considered the standard for establishing the diagnosis of bilateral diaphragmatic paralysis,[14,20,54] the tests are invasive and uncomfortable.

Ultrasonography of the diaphragm at its zone of apposition with the rib cage is a noninvasive technique that can be used to measure changes in the thickness of the diaphragm during inspiration (Fig. 5; and Video 1, available at NEJM.org). Thickening of the diaphragm reflects diaphragmatic shortening,[55] and a lack of thickening with inspiration is diagnostic of diaphragmatic paralysis (Video 2).[56] Because ultrasonography can distinguish a functioning from a nonfunctioning diaphragm, it can be used to diagnose both unilateral and bilateral diaphragmatic paralysis and to monitor recovery of the paralyzed diaphragm.[24,56] Ultrasonography of the diaphragmatic dome has also been reported as a method for documenting diaphragmatic paralysis in adults[57,58] and children[59]; however, this technique primarily images the central tendon of the diaphragm, not the muscular component, and is subject to limitations similar to those of fluoroscopy of the diaphragm.

Electromyography of the diaphragm can be performed during quiet breathing or during stimulation of the phrenic nerve. Its role in the diagnosis of diaphragmatic paralysis or weakness is limited by a number of technical issues, including the proper placement of electrodes, the possibility of electromyographic "cross-talk" from adjacent muscles, and the variable distances between muscles and electrodes that result from differences in subcutaneous fat among patients.[11,60] However, electromyography of the diaphragm may be useful in distinguishing between neuropathic and myopathic causes of known diaphragmatic dysfunction.

The New England Journal of Medicine
Downloaded from nejm.org at UNIVERSITY OF EDINBURGH LIB on January 28, 2019. For personal use only. No other uses without permission.
Copyright © 2012 Massachusetts Medical Society. All rights reserved.

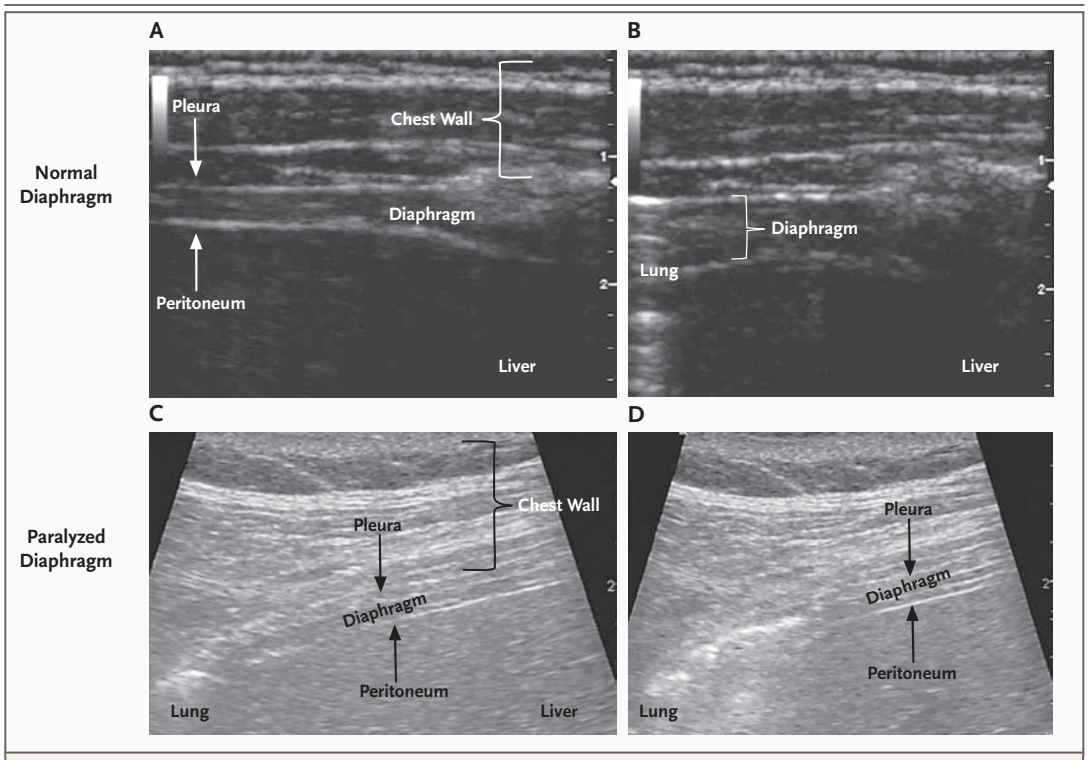

Figure 5. Ultrasonographic Images of Normal and Paralyzed Diaphragms.

Panels A and B show the end-expiration and end-inspiration stages, respectively, in a normal diaphragm. Panels C and D show the end-expiration and end-inspiration stages, respectively, in a paralyzed diaphragm. During inspiration, the normal diaphragm thickens, whereas the paralyzed diaphragm does not thicken.

TREATMENT

The treatment of patients with diaphragmatic dysfunction depends on the cause and on the presence or absence of symptoms and nocturnal hypoventilation. Examples of treatable causes of diaphragmatic dysfunction include myopathies related to metabolic disturbances such as hypokalemia, hypomagnesemia, hypocalcemia, and hypophosphatemia. Correction of electrolyte and hormonal imbalances and avoidance of neuropathic or neuromuscular blocking agents can restore strength in the diaphragm. Myopathies due to parasitic infection (e.g., trichinosis) may respond to appropriate antimicrobial agents.[61] Idiopathic diaphragmatic paralysis or paralysis due to neuralgic amyotrophy may improve spontaneously.[13] When diaphragmatic dysfunction persists or progresses, ventilatory support, ranging from nocturnal to continuous, may be needed. The need for ventilatory support may be temporary, as in cases of diaphragmatic paralysis after cardiac surgery, or it may be permanent, as in cases of progressive neuromuscular diseases. The generally accepted indications for initiating nocturnal noninvasive ventilation in patients with symptoms include a partial pressure of carbon dioxide of 45 mm Hg or higher in the arterial blood in the daytime, oxygen saturation of 88% or less for 5 consecutive minutes at night, or progressive neuromuscular disease with a maximal static inspiratory pressure of less than 60 cm of water or a forced vital capacity of less than 50% of the predicted value.[62] Most patients with neuromuscular disease will eventually require mechanical ventilation, whether it is provided by invasive means (tracheostomy or endotracheal tube) or noninvasive means (nasal cannula or face mask).

Plication of the diaphragm is a procedure in which the flaccid hemidiaphragm is made taut by oversewing the membranous central tendon and the muscular components of the diaphragm. The indications and timing for this procedure are not fully defined, given that most studies are retrospective and uncontrolled, but it may be offered to patients with unilateral diaphragmatic paralysis

The New England Journal of Medicine
Downloaded from nejm.org at UNIVERSITY OF EDINBURGH LIB on January 28, 2019. For personal use only. No other uses without permission.
Copyright © 2012 Massachusetts Medical Society. All rights reserved.

who have severe dyspnea, cough, or chest pain or who are ventilator-dependent.[63] Plication of the diaphragm may result in increases of up to 20% in vital capacity, forced expiratory volume in 1 second, and total lung capacity, along with improvement in dyspnea.[63,64] The increase in lung volumes related to plication results from immobilization of the diaphragm, which lessens its paradoxical motion.[65] In general, a long period of observation should be considered before plication is recommended. This is especially true for patients with unilateral diaphragmatic paralysis after cardiac surgery or other surgical procedures that involve the cervical or mediastinal regions, since phrenic function may improve with time.[12,24,66] Morbid obesity and progressive neuromuscular diseases are relative contraindications to plication of the diaphragm.[67] Plication is unlikely to be helpful in bilateral diaphragmatic paralysis.

Phrenic pacing has the potential to provide full ventilatory support for ventilator-dependent patients who have bilateral diaphragmatic paralysis and intact phrenic nerves. Candidates for this method of treatment are primarily patients with high cervical cord quadriplegia or patients with central hypoventilation. Despite technical improvements in phrenic-pacing systems, activation of the diaphragm does not provide sustained, full ventilatory support.[68] Newer methods that use laparoscopic mapping of motor points and intramuscular stimulation of the diaphragm have shown promising results.[69]

Sleep-disordered breathing is common among patients with diaphragmatic dysfunction, since suppression of the activity of accessory inspiratory muscles during rapid-eye-movement sleep leads to hypoventilation.[17,70] In patients with severe diaphragmatic weakness or unilateral diaphragmatic paralysis, sleep-disordered breathing develops independently of body-mass index, sex, and age.[17] Among patients with unilateral diaphragmatic paralysis, sleep-disordered breathing is primarily found in those with clinically significant weakness (unilateral twitch Pdi, <5 cm of water).[17] Patients with diaphragmatic weakness that is due to a neuromuscular disease, such as muscular dystrophy or amyotrophic lateral sclerosis, may also have obstructive sleep apnea. Weakness of pharyngeal and laryngeal muscles may predispose these patients to airway collapse during inspiration.[70] As with other causes of sleep-disordered breathing, noninvasive positive-pressure ventilation is the preferred method of treatment for patients with diaphragmatic paralysis because it can improve both symptoms and physiological derangements.

An increase in the use of ultrasonography is likely to lead to prompt identification of patients with diaphragmatic dysfunction, and further innovations in noninvasive ventilation will lead to more physiologic and comfortable ventilatory support for these persons. Advances in intramuscular pacing and treatment of congenital myopathies with enzyme-replacement or gene-transfer therapy may provide further hope for effective treatment.

Disclosure forms provided by the authors are available with the full text of this article at NEJM.org.

REFERENCES

1. Al-Bilbeisi F, McCool FD. Diaphragm recruitment during nonrespiratory activities. Am J Respir Crit Care Med 2000; 162:456-9.
2. Loring SH, Mead J. Action of the diaphragm on the rib cage inferred from a force-balance analysis. J Appl Physiol 1982;53:756-60.
3. Laghi F, Tobin MJ. Disorders of the respiratory muscles. Am J Respir Crit Care Med 2003;168:10-48.
4. Gibson GJ. Diaphragmatic paresis: pathophysiology, clinical features, and investigation. Thorax 1989;44:960-70.
5. Kumar N, Folger WN, Bolton CF. Dyspnea as the predominant manifestation of bilateral phrenic neuropathy. Mayo Clin Proc 2004;79:1563-5.
6. Wilcox PG, Pardy RL. Diaphragmatic weakness and paralysis. Lung 1989;167: 323-41.
7. Davison A, Mulvey D. Idiopathic diaphragmatic weakness. BMJ 1992;304:492-4.
8. McCool FD, Mead J. Dyspnea on immersion: mechanisms in patients with bilateral diaphragm paralysis. Am Rev Respir Dis 1989;139:275-6.
9. Mier AK, Brophy C, Green M. Out of depth, out of breath. Br Med J (Clin Res Ed) 1986;292:1495-6.
10. Mier-Jedrzejowicz A, Brophy C, Moxham J, Green M. Assessment of diaphragm weakness. Am Rev Respir Dis 1988;137:877-83.
11. Chan CK, Loke J, Virgulto JA, Mohsenin V, Ferranti R, Lammertse T. Bilateral diaphragmatic paralysis: clinical spectrum, prognosis, and diagnostic approach. Arch Phys Med Rehabil 1988;69:976-9.
12. Efthimiou J, Butler J, Woodham C, Benson MK, Westaby S. Diaphragm paralysis following cardiac surgery: role of phrenic nerve cold injury. Ann Thorac Surg 1991;52:1005-8.
13. Hughes PD, Polkey MI, Moxham J, Green M. Long-term recovery of diaphragm strength in neuralgic amyotrophy. Eur Respir J 1999;13:379-84.
14. Laroche CM, Mier AK, Moxham J, Green M. Diaphragm strength in patients with recent hemidiaphragm paralysis. Thorax 1988;43:170-4. [Erratum, Thorax 1988;43:583.]
15. Hart N, Nickol AH, Cramer D, et al. Effect of severe isolated unilateral and bilateral diaphragm weakness on exercise performance. Am J Respir Crit Care Med 2002;165:1265-70.
16. Lisboa C, Paré PD, Pertuzé J, et al. Inspiratory muscle function in unilateral diaphragmatic paralysis. Am Rev Respir Dis 1986;134:488-92.
17. Steier J, Jolley CJ, Seymour J, et al.

The New England Journal of Medicine
Downloaded from nejm.org at UNIVERSITY OF EDINBURGH LIB on January 28, 2019. For personal use only. No other uses without permission.
Copyright © 2012 Massachusetts Medical Society. All rights reserved.

Sleep-disordered breathing in unilateral diaphragm paralysis or severe weakness. Eur Respir J 2008;32:1479-87.
18. Skatrud J, Iber C, McHugh W, Rasmussen H, Nichols D. Determinants of hypoventilation during wakefulness and sleep in diaphragmatic paralysis. Am Rev Respir Dis 1980;121:587-93.
19. Stradling JR, Warley AR. Bilateral diaphragm paralysis and sleep apnoea without diurnal respiratory failure. Thorax 1988; 43:75-7.
20. Davis J, Goldman M, Loh L, Casson M. Diaphragm function and alveolar hypoventilation. Q J Med 1976;45:87-100.
21. Laroche CM, Carroll N, Moxham J, Green M. Clinical significance of severe isolated diaphragm weakness. Am Rev Respir Dis 1988;138:862-6.
22. Lahrmann H, Grisold W, Authier FJ, Zifko UA. Neuralgic amyotrophy with phrenic nerve involvement. Muscle Nerve 1999;22:437-42.
23. Oo T, Watt JW, Soni BM, Sett PK. Delayed diaphragm recovery in 12 patients after high cervical spinal cord injury: a retrospective review of the diaphragm status of 107 patients ventilated after acute spinal cord injury. Spinal Cord 1999; 37:117-22.
24. Summerhill EM, El-Sameed YA, Glidden TJ, McCool FD. Monitoring recovery from diaphragm paralysis with ultrasound. Chest 2008;133:737-43.
25. Tsairis P, Dyck PJ, Mulder DW. Natural history of brachial plexus neuropathy: report on 99 patients. Arch Neurol 1972; 27:109-17.
26. Chawla J, Gruener G. Management of critical illness polyneuropathy and myopathy. Neurol Clin 2010;28:961-77.
27. Howard RS, Wiles CM, Hirsch NP, Loh L, Spencer GT, Newsom-Davis J. Respiratory involvement in multiple sclerosis. Brain 1992;115:479-94.
28. Wicks AB, Menter RR. Long-term outlook in quadriplegic patients with initial ventilator dependency. Chest 1986;90:406-10.
29. Dahan V, Kimoff RJ, Petrof BJ, Benedetti A, Diorio D, Trojan DA. Sleep-disordered breathing in fatigued postpoliomyelitis clinic patients. Arch Phys Med Rehabil 2006;87:1352-6.
30. Piehler JM, Pairolero PC, Gracey DR, Bernatz PE. Unexplained diaphragmatic paralysis: a harbinger of malignant disease? J Thorac Cardiovasc Surg 1982;84:861-4.
31. Salati M, Cardillo G, Carbone L, et al. Iatrogenic phrenic nerve injury during thymectomy: the extent of the problem. J Thorac Cardiovasc Surg 2010;139(4):e77-e78.
32. Merino-Ramirez MA, Juan G, Ramón M, et al. Electrophysiologic evaluation of phrenic nerve and diaphragm function after coronary bypass surgery: prospective study of diabetes and other risk factors. J Thorac Cardiovasc Surg 2006;132:530-6.
33. Wheeler WE, Rubis LJ, Jones CW, Harrah JD. Etiology and prevention of topical cardiac hypothermia-induced phrenic nerve injury and left lower lobe atelectasis during cardiac surgery. Chest 1985;88: 680-3.
34. Cosi V, Versino M. Guillain-Barré syndrome. Neurol Sci 2006;27:Suppl 1:S47-S51.
35. van Doorn PA, Ruts L, Jacobs BC. Clinical features, pathogenesis, and treatment of Guillain-Barré syndrome. Lancet Neurol 2008;7:939-50.
36. Diehl JL, Lofaso F, Deleuze P, Similowski T, Lemaire F, Brochard L. Clinically relevant diaphragmatic dysfunction after cardiac operations. J Thorac Cardiovasc Surg 1994;107:487-98.
37. Mills GH, Kyroussis D, Hamnegard CH, et al. Cervical magnetic stimulation of the phrenic nerves in bilateral diaphragm paralysis. Am J Respir Crit Care Med 1997;155:1565-9.
38. Laroche CM, Mier AK, Spiro SG, Newsom-Davis J, Moxham J, Green M. Respiratory muscle weakness in the Lambert-Eaton myasthenic syndrome. Thorax 1989; 44:913-8.
39. Witoonpanich R, Vichayanrat E, Tantisiriwit K, et al. Survival analysis for respiratory failure in patients with foodborne botulism. Clin Toxicol (Phila) 2010; 48:177-83.
40. Jaber S, Petrof BJ, Jung B, et al. Rapidly progressive diaphragmatic weakness and injury during mechanical ventilation in humans. Am J Respir Crit Care Med 2011;183:364-71.
41. Levine S, Nguyen T, Taylor N, et al. Rapid disuse atrophy of diaphragm fibers in mechanically ventilated humans. N Engl J Med 2008;358:1327-35.
42. Levine S, Budak MT, Dierov J, Singhal S. Inactivity-induced diaphragm dysfunction and mitochondria-targeted antioxidants: new concepts in critical care medicine. Crit Care Med 2011;39:1844-5.
43. Knochel JP. Neuromuscular manifestations of electrolyte disorders. Am J Med 1982;72:521-35.
44. McParland C, Resch EF, Krishnan B, Wang Y, Cujec B, Gallagher CG. Inspiratory muscle weakness in chronic heart failure: role of nutrition and electrolyte status and systemic myopathy. Am J Respir Crit Care Med 1995;151:1101-7.
45. Decramer M. Effects of hyperinflation on the respiratory muscles. Eur Respir J 1989;2:299-302.
46. Tzelepis G, McCool FD, Leith DE, Hoppin FG Jr. Increased lung volume limits endurance of inspiratory muscles. J Appl Physiol 1988;64:1796-802.
47. Estenne M. Effect of lung transplant and volume reduction surgery on respiratory muscle function. J Appl Physiol 2009; 107:977-86.
48. Lando Y, Boiselle PM, Shade D, et al. Effect of lung volume reduction surgery on diaphragm length in severe chronic obstructive pulmonary disease. Am J Respir Crit Care Med 1999;159:796-805.
49. O'Donnell DE. Hyperinflation, dyspnea, and exercise intolerance in chronic obstructive pulmonary disease. Proc Am Thorac Soc 2006;3:180-4.
50. Chetta A, Rehman AK, Moxham J, Carr DH, Polkey MI. Chest radiography cannot predict diaphragm function. Respir Med 2005;99:39-44.
51. Alexander C. Diaphragm movements and the diagnosis of diaphragmatic paralysis. Clin Radiol 1966;17:79-83.
52. Polkey MI, Green M, Moxham J. Measurement of respiratory muscle strength. Thorax 1995;50:1131-5.
53. Steier J, Kaul S, Seymour J, et al. The value of multiple tests of respiratory muscle strength. Thorax 2007;62:975-80.
54. Mier A, Brophy C, Moxham J, Green M. Twitch pressures in the assessment of diaphragm weakness. Thorax 1989;44: 990-6.
55. Cohn D, Benditt JO, Eveloff S, McCool FD. Diaphragm thickening during inspiration. J Appl Physiol 1997;83:291-6.
56. Gottesman E, McCool FD. Ultrasound evaluation of the paralyzed diaphragm. Am J Respir Crit Care Med 1997;155:1570-4.
57. Houston JG, Fleet M, Cowan MD, McMillan NC. Comparison of ultrasound with fluoroscopy in the assessment of suspected hemidiaphragmatic movement abnormality. Clin Radiol 1995;50:95-8.
58. McCauley RG, Labib KB. Diaphragmatic paralysis evaluated by phrenic nerve stimulation during fluoroscopy or real-time ultrasound. Radiology 1984;153:33-6.
59. Ambler R, Gruenewald S, John E. Ultrasound monitoring of diaphragm activity in bilateral diaphragmatic paralysis. Arch Dis Child 1985;60:170-2.
60. Saadeh PB, Crisafulli CF, Sosner J, Wolf E. Needle electromyography of the diaphragm: a new technique. Muscle Nerve 1993;16:15-20.
61. Clausen MR, Meyer CN, Krantz T, et al. Trichinella infection and clinical disease. QJM 1996;89:631-6.
62. Clinical indications for noninvasive positive pressure ventilation in chronic respiratory failure due to restrictive lung disease, COPD, and nocturnal hypoventilation — a consensus conference report. Chest 1999;116:521-34.
63. Freeman RK, Van Woerkom J, Vyverberg A, Ascioti AJ. Long-term follow-up of the functional and physiologic results of diaphragm plication in adults with unilateral diaphragm paralysis. Ann Thorac Surg 2009;88:1112-7.
64. Mouroux J, Venissac N, Leo F, Alifano M, Guillot F. Surgical treatment of diaphragmatic eventration using video-assisted thoracic surgery: a prospective study. Ann Thorac Surg 2005;79:308-12.
65. Ciccolella DE, Daly BD, Celli BR. Im-

The New England Journal of Medicine
Downloaded from nejm.org at UNIVERSITY OF EDINBURGH LIB on January 28, 2019. For personal use only. No other uses without permission.
Copyright © 2012 Massachusetts Medical Society. All rights reserved.

proved diaphragmatic function after surgical plication for unilateral diaphragmatic paralysis. Am Rev Respir Dis 1992; 146:797-9.
66. Gayan-Ramirez G, Gosselin N, Troosters T, Bruyninckx F, Gosselink R, Decramer M. Functional recovery of diaphragm paralysis: a long-term follow-up study. Respir Med 2008;102:690-8.
67. Groth SS, Andrade RS. Diaphragm plication for eventration or paralysis: a review of the literature. Ann Thorac Surg 2010;89:S2146-S2150.
68. DiMarco AF, Kowalski KE. High-frequency spinal cord stimulation of inspiratory muscles in dogs: a new method of inspiratory muscle pacing. J Appl Physiol 2009;107:662-9.
69. Onders RP, Elmo M, Khansarinia S, et al. Complete worldwide operative experience in laparoscopic diaphragm pacing: results and differences in spinal cord injured patients and amyotrophic lateral sclerosis patients. Surg Endosc 2009;23: 1433-40.
70. Bourke SC, Gibson GJ. Sleep and breathing in neuromuscular disease. Eur Respir J 2002;19:1194-201.
Copyright © 2012 Massachusetts Medical Society.

Brown Pelican Nigil Haroon, M.D.

The New England Journal of Medicine
Downloaded from nejm.org at UNIVERSITY OF EDINBURGH LIB on January 28, 2019. For personal use only. No other uses without permission.
Copyright © 2012 Massachusetts Medical Society. All rights reserved.